

Clinical and Histologic Assessment of Lateral Alveolar Ridge Augmentation Using a Synthetic Long-Term Bioabsorbable Membrane and an Allograft

Nicolaas C. Geurs,* Jonathan M. Korostoff,† Philip J. Vassilopoulos,* Tae-Heon Kang,† Marjorie Jeffcoat,† Robert Kellar,‡ and Michael S. Reddy*

Background: Guided bone regeneration (GBR) is a widely used procedure for augmenting alveolar ridge width prior to placement of endosseous implants. Various graft materials and barrier membranes (non-resorbable and bioabsorbable) have been used in GBR. The aim of this study was to assess the performance of a new bioabsorbable, synthetic polyglycolic acid/trimethylene carbonate (PGA/TMC) barrier membrane with an increased absorption time in conjunction with a combination of assayed demineralized bone matrix and cortical cancellous chips uniformly dispersed in a thermoplastic biologic carrier.

Methods: At 72 potential implant sites in 38 subjects, ridge width at the crest and 4 mm apical to the crest was measured before and 6 months after a GBR procedure using the long-term (LT) PGA/TMC membrane and an allograft in a thermoplastic carrier. Before placement of endosseous implants, 48 biopsy specimens were obtained from the augmentation sites and analyzed histomorphometrically.

Results: The GBR procedure increased the mean ridge width at the crest from 2.4 to 5.2 mm. This 216% change from baseline was significant ($P < 0.001$). The mean width 4 mm apical to the crest increased from 4.4 to 7.5 mm, a significant ($P < 0.001$) 174% change. The histomorphometric analysis showed that the biopsy specimens consisted, on average, of 57% bone (36% graft material and 21% new bone) and 43% soft tissue and space.

Conclusion: Our findings suggest that the LT PGA/TMC barrier membrane, used in conjunction with an allograft, provides lateral alveolar ridge augmentation comparable to that achieved with other materials without the necessity for bone-graft harvesting or a second procedure to remove the barrier membrane. *J Periodontol* 2008;79:1133-1140.

KEY WORDS

Alveolar ridge augmentation; bone regeneration; polyglycolic acid/trimethylene carbonate.

Without intervention, alveolar ridge resorption following tooth loss seems to be inevitable and irreversible; it often occurs quickly, especially within the first 6 months after a tooth is lost.^{1,2} Typically, resorption takes place at the expense of facial or buccal bone, leading to the development of a variety of ridge deformities.^{2,3} The associated loss in ridge width may preclude placement of endosseous dental implants and, therefore, represents a major challenge in implant dentistry.³

Several methods for augmenting the alveolar ridge in preparation for implant placement have been described. Among these techniques, guided bone regeneration (GBR) has probably generated the most interest.^{4,5} The concept of GBR is based upon the use of a barrier membrane to exclude rapidly growing soft tissue cells from a bony defect and, more importantly, to maintain a space for the slower process of bone formation.⁴ Bone grafts or bone substitutes are commonly used in GBR procedures to provide support for the barrier membrane, for additional

* Department of Periodontology, University of Alabama at Birmingham School of Dentistry, Birmingham, AL.

† Department of Periodontics, University of Pennsylvania School of Dental Medicine, Philadelphia, PA.

‡ W.L. Gore & Associates, Inc., Flagstaff, AZ.

space maintenance, and/or for their osteoconductive/osteoinductive properties.

Historically, most initial GBR procedures, especially those in patients not undergoing immediate implant placement, used autogenous bone and a non-resorbable barrier membrane composed of expanded polytetrafluoroethylene (ePTFE).⁶⁻⁸ This approach resulted in adequate lateral ridge augmentation and favorable long-term survival of subsequently inserted implants.^{5,9-12} Despite these encouraging results, there are drawbacks to using autogenous bone and non-resorbable ePTFE membranes for GBR. Although the use of autogenous bone ensures biocompatibility and provides viable osteogenic cells, it also necessitates a separate bone-harvesting procedure.⁸ In some cases, bone must be obtained from an extraoral site by a surgeon with the appropriate expertise. Furthermore, the need to remove the membrane, if not done in conjunction with implant placement, adds an additional surgical procedure to the treatment protocol. The added time, expense, and potential morbidity are recognized impediments to patient acceptance of such procedures. Premature exposure and possible premature removal of non-resorbable membranes have been associated with diminished results.^{5-7,9} Because of these drawbacks, the most recent GBR research has included a strong focus on augmentation procedures using different bone graft materials (allogenic, xenogenic, and alloplastic) in combination with bioabsorbable barrier membranes. Promising results with these materials have been reported in animal studies^{13,14} and human clinical investigations.¹⁵⁻¹⁷

Barrier membranes made of bovine or porcine collagen^{18,19} or synthetic polymers,^{3,14} including a membrane composed of polyglycolic acid/trimethylene carbonate (PGA/TMC§),^{20,21} are the most widely studied bioabsorbable materials for GBR. Collagen has several desirable properties, including its hemostatic, chemotactic, and cell-adhesion functions,²² and has yielded favorable results in clinical trials of GBR for ridge-width augmentation.²³ However, as noted by Bunyaratavej and Wang,¹⁸ collagen's fast absorption rate remains a concern to most clinicians. This issue provoked the development of a new bioabsorbable, synthetic membrane of 67% PGA and 33% TMC that was designed to remain intact for 16 to 25 weeks.

A prototype of the long-term (LT) PGA/TMC¶ membrane was compared to a collagen membrane in a GBR study in dogs.²⁴ In this investigation, teeth were extracted, and osseous defects were created. Defects were filled with a demineralized freeze-dried bone allograft in a thermoplastic gelatin matrix alone (control) or covered with a collagen membrane or an LT PGA/TMC membrane. Three months later, the dogs

were sacrificed, and representative tissue sections were prepared from the defects and subjected to histomorphometric analysis. Sites covered with a PGA/TMC membrane showed a significantly higher percentage of bone regeneration and less soft tissue relative to sites covered with collagen membranes. Control sites showed deformation of regenerated bone resulting from collapse of the overlying periosteum. These findings provided initial evidence of the effectiveness of the combination of an allograft and the PGA/TMC membrane for GBR in edentulous areas.

The purpose of the current study was to evaluate the efficacy of LT PGA/TMC membranes when used in conjunction with a combination of assayed demineralized bone matrix and cortical cancellous chips uniformly dispersed in a thermoplastic biologic carrier¶ for GBR of lateral ridge defects in humans. The specific aim of the study was to assess the quantity and quality of augmented bone achieved with these unique materials by means of clinical and histologic criteria.

MATERIALS AND METHODS

Subject Population

This two-center study was conducted at the University of Alabama at Birmingham School of Dentistry and the University of Pennsylvania School of Dental Medicine from November 2003 through March 2005. Individuals who participated in the study required an endosseous implant in at least one healed bony site that exhibited adequate ridge height but insufficient ridge width (defined as ≤ 5 mm on bone sounding) for implantation. Subjects with medical conditions or lifestyle factors likely to affect healing were excluded from the study, including those with uncontrolled diabetes, immune disease, history of alcohol or drug abuse, current smokers, or individuals deemed to be a compliance risk. Fifty-one subjects (41 men and 10 women; mean age: 53 years; age range, 24 to 77 years) with 98 potential implant sites were enrolled into the investigation. The protocol was approved by the institutional review boards of the authors' universities, and all subjects provided written informed consent.

Ridge Augmentation Procedure

A treatment plan for placement and restoration of dental implants was derived by a team of surgeons and prosthodontists of the graduate programs in periodontology and prosthodontics at both centers. A surgical guide was fabricated to facilitate accurate

§ Gore Resolut XT Regenerative Membrane, W.L. Gore & Associates, Inc., Flagstaff, AZ.

¶ Gore Resolut Adapt LT Regenerative Membrane, W.L. Gore & Associates, Inc.

¶¶ Regenaform Moldable Allograft Paste, Exactech Dental Biologics, Gainesville, FL.

implant placement and to ensure that pre- and post-augmentation measurements were taken at the same anatomic location. All subjects received an antibiotic agent (cephalexin, 2 g, or if allergic, clindamycin, 600 mg) 30 minutes before the ridge-augmentation surgery. The surgical procedure was performed using local anesthesia and intravenous sedation, when indicated. A crestal incision was made above the treatment site, and full-thickness flaps were reflected to allow access to the site. Potential implant-placement sites were located with the surgical guide. The test sites were located with the surgical guide identifying the implant sites, and ridge width at the crest and 4 mm apical to the crest of each future implant site was measured with ridge-mapping calipers. An LT PGA/TMC membrane was shaped with a fabricated template and fitted to the area requiring augmentation. The membrane was tailored to cover the ridge, allograft, and ≥ 3 mm of native bone while remaining ≥ 1 mm from any adjacent teeth.

Prior to placement of the allograft, the bone defect was decorticated with a high-speed drill using a #2 round bur with perforations made at 4-mm intervals in the cortical plate. Periosteal release was performed to allow for tension-free closure over the membrane and graft. The thermoplastic nature of the biologic carrier of the allograft allows for manipulation and modeling of the graft for ~ 2 minutes, after which it sets up to a rubbery consistency with dimensional stability. The material was shaped to dimensions that provided adequate augmentation of the defective ridge, set in place, and covered with the trimmed LT PGA/TMC membrane. To keep the surgical procedure simple and because of the dimensional stability of the graft, no pins and/or tacks for supporting and/or anchoring the membrane were used. Primary wound closure was achieved with a combination of continuous interlocking mattress and interrupted ePTFE sutures.[#] An analgesic agent was given according to the clinician's and subject's preference. An antibiotic was prescribed as a continuation of the premedication regimen and consisted of cephalexin, 500 mg, every 8 hours for 7 days or clindamycin, 300 mg, every 8 hours for 7 days. Subjects were instructed to rinse their mouths with a 0.12% chlorhexidine mouthrinse twice daily for 2 weeks. Sutures were removed, and healing in the operative sites was confirmed at a 2-week postoperative clinical examination.

Implant Procedure

Endosseous implant surgery was performed ~ 6 months after the ridge-augmentation procedure. Full-thickness flaps were reflected, and study sites were identified with the original surgical guide. Ridge width measurements at the crest and 4 mm apical to the crest of each site were repeated. A biopsy speci-

men of one treatment site per separate augmentation site was obtained using a 2-mm trephine inserted to a depth of 6 mm in the same position and at the same angle planned for the endosseous implants. Specimens were stored inside the trephine, which was placed in formalin and subsequently processed for histomorphometric analysis. Placement of the endosseous implants was done in accordance with the authors' standard protocol.

Histomorphometry

The trephines containing the biopsy specimens were embedded in polymethylmethacrylate, and a section for analysis was cut from the middle of the block. The sections were treated with Paragon stain that showed vital bone as dark red, non-vital bone as light red, and marrow spaces, soft tissue, and cells as various shades of blue. An image analysis system^{**} was used to determine the proportions of vital and non-vital bone in the specimens.

Calculation of Ridge Width Changes and Statistical Analysis

The values for ridge width change at the crest and 4 mm apical to the crest were calculated by subtracting the values for the initial ridge width measurement from the corresponding values obtained 6 months later at the time of implant placement. A one-sided Student *t* test was used to evaluate the change in ridge width. A *P* value < 0.05 was considered to represent a significant difference between ridge width before and 6 months after placement of the allograft and LT PGA/TMC membrane.

RESULTS

Fifty-one subjects with 98 potential implant sites were enrolled in the investigation at the two study centers. Thirteen subjects subsequently withdrew from the study because of health problems, including cancer (two subjects) and temporomandibular disorder (one subject); financial reasons (two subjects); or unknown reasons (eight subjects). Thirty-eight subjects returned for the 6-month assessment and implant placement; 48 ridges were augmented in this group. Thirty subjects had one, six subjects had two, and two subjects had three ridge augmentations. Thus, the reported comparisons between ridge width values at the initial evaluation and 6 months later were based on measurements at 72 sites in 38 subjects.

Clinical Observations

At flap reflection for placement of the endosseous implants, no LT PGA/TMC membranes or remnants of these membranes were observed. Figure 1 shows the mean \pm SD values for ridge width at the crest

[#] CV-5 Gore-Tex Suture, W.L. Gore & Associates, Inc.
^{**} Nova Prime, Bioquant Image Analysis, Nashville, TN.

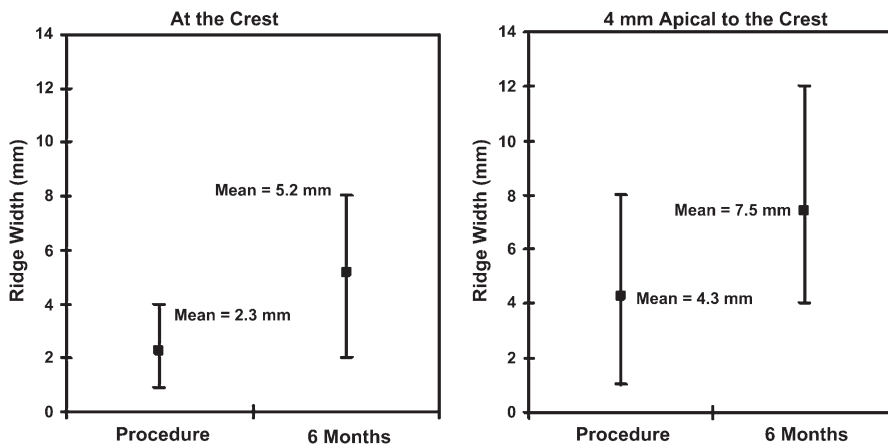


Figure 1. Mean (\pm SD) values ($N = 72$ sites) for alveolar ridge width at crest and 4 mm apical to the crest before augmentation procedure and 6 months after ridge-augmentation procedure.

Table 1. Distribution of Sites in Relation to the Change From Baseline (mm)

Change	<1	1 to <2	2 to <3	3 to <4	4 to <5	5 to <6	6+
At the crest (n)	6	12	22	9	12	5	6
4 mm apical to the crest (n)	6	8	20	11	10	9	8

and 4 mm apical to the crest before and 6 months after the GBR procedure. For ridge width at the crest, there was a mean increase of 2.8 ± 1.7 mm (range, 0 to 7 mm). This change was significant ($P < 0.001$). For ridge width 4 mm apical to the crest, a mean increase of 3.1 ± 1.9 mm (range, -0.5 to 7 mm) occurred. This change from baseline was statistically significant ($P < 0.001$). The change in ridge width for all individual sites is represented in Table 1. It shows the distribution of the individual sites with the change that was observed from baseline. Only a few sites demonstrated no gain in width at the crest, and all sites showed an increase in width at one of the measuring points. Figure 2 shows a representative mandibular lateral ridge augmentation performed with the LT PGA/TMC membrane in conjunction with a combination of assayed demineralized bone matrix and cortical cancellous chips uniformly dispersed in a thermoplastic biologic carrier. Figure 3 represents another case with the ridge before and 6 months after augmentation.

Histomorphometry

Forty-eight treatment sites were included in the histomorphometric analysis. Every ridge area that was

augmented contributed one biopsy site. The analysis of the composition of the 48 specimens found the following (mean \pm SD) proportions: $36.2\% \pm 15\%$ graft material, $20.6\% \pm 8.8\%$ new bone, and $49.9\% \pm 17.3\%$ soft tissue and space. The mean proportion of total bone (residual graft and new bone) was 56.8%.

Figure 4 shows representative histologic sections prepared from the biopsy specimens. Histomorphometric analysis demonstrated new bone formation. The general findings show evidence of remodeling and new bone surrounding the implanted bone fragments. Marrow tissue was consistently observed.

Active remodeling of the allograft was evident by the presence of osteoid and osteoblasts. The new bone appears woven and has viable osteocytes. In some sections, the remodeling of the allograft fragments was almost complete.

Complications

One subject complained of temporomandibular joint pain after the surgery. It was found to be a preexisting condition of a temporomandibular disorder that was not reported by the subject upon enrollment. One subject reported paresthesia that resolved spontaneously within a month. Two fistulas were noted at postoperative evaluations and resolved after antibiotic treatment.

Membrane Exposure

Overall, membrane exposure occurred at 30 of the 72 study sites (42%). Eight (11%) of the exposed membranes necessitated premature removal. When a membrane became exposed, the subject was instructed to locally apply 0.12% chlorhexidine to the area twice a day. The membranes that were removed showed localized signs of infection. All infections resolved without further intervention after membrane removal. Table 2 summarizes the ridge width changes for the different exposure status.

DISCUSSION

This study evaluated the effectiveness of a new bioabsorbable, synthetic LT PGA/TMC membrane used in conjunction with a bone allograft to augment alveolar ridge width in healed bony sites in preparation for placement of endosseous dental implants. In a majority of the treated cases, there were significant increases in ridge width at the crest and 4 mm apical to the crest relative to presurgical values. Because

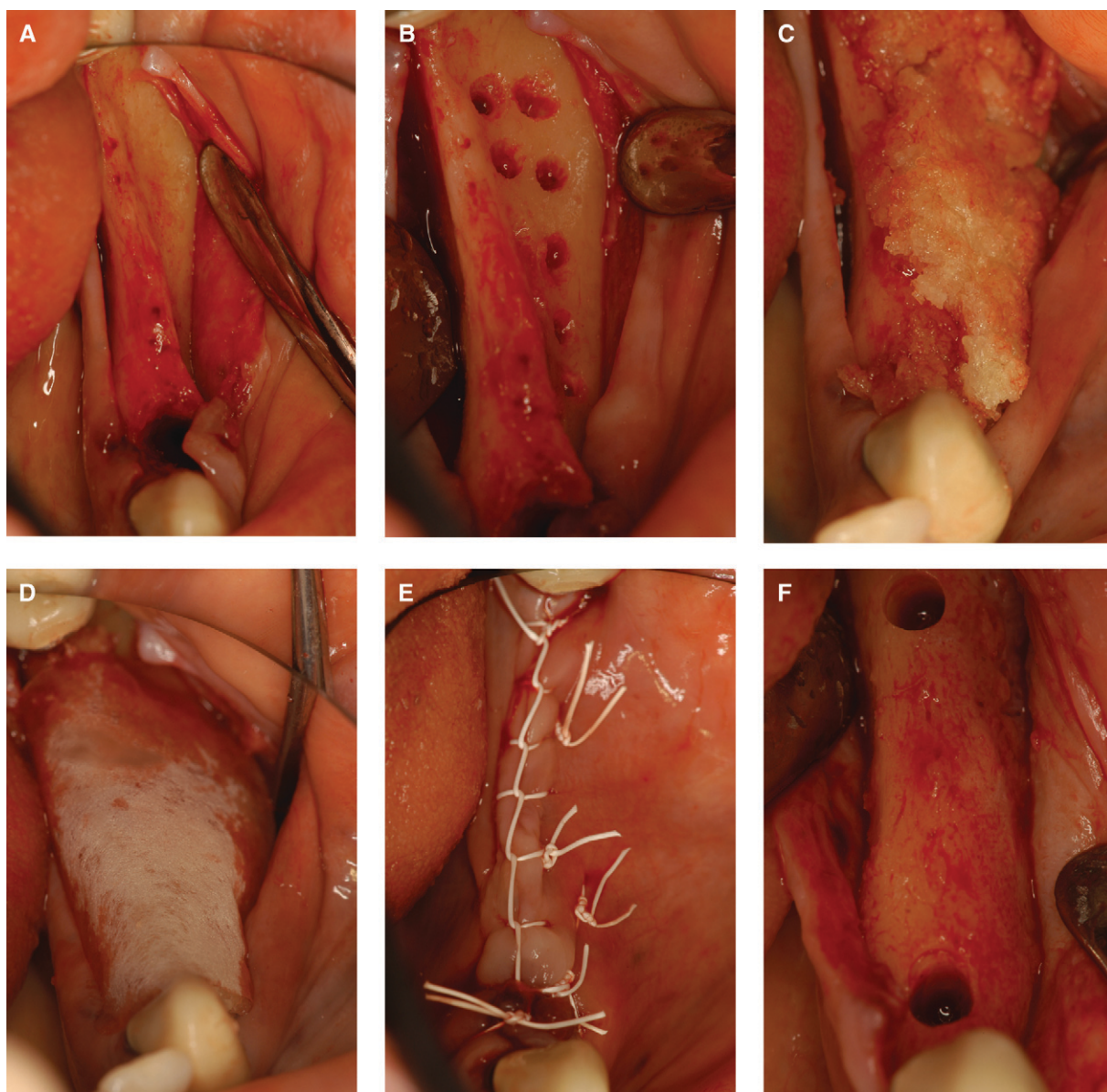


Figure 2.

A) The ridge after reflection of the flaps. **B)** The cortical perforations. **C)** The thermoplastic allograft in place. **D)** The membrane adapted over the graft. **E)** Primary closure with ePTFE sutures. **F)** The ridge 6 months after the ridge augmentation.

we measured the ridge at two locations, our assessment indicated that augmentation occurred along the entire ridge, thereby further enhancing the potential implant sites. GBR using an LT PGA/TMC membrane and an allograft was reported to provide effective ridge augmentation in dogs.²⁴ However, to our knowledge, the present study represents the first human clinical investigation of this technique. The results are in accordance with those of the animal study²⁴ and indicate that this particular membrane and allograft material effectively promoted increases in ridge width in healed bony defects for which delayed implantation was planned.

The allograft used in this study has several advantageous characteristics. The gelatin matrix in which it is suspended is thermoplastic and sets to a rubbery consistency. After setting, it has dimensional stability. These features facilitate the subsequent placement of the membrane because graft displacement is avoided, and tacks are not required to stabilize the membrane. Most important, using an allograft eliminates the need for a procedure to harvest autogenous bone for grafting. Studies in animals¹⁴ and humans²² showed that allografts could provide results comparable to those achieved with autogenous bone.

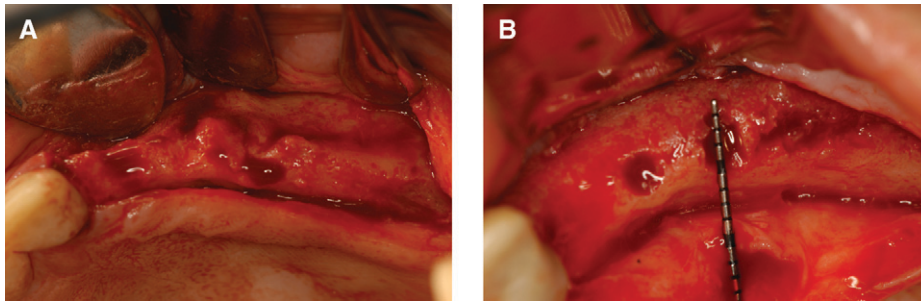


Figure 3.

A) The ridge after reflection of the flaps. **B)** The ridge 6 months after the ridge augmentation.

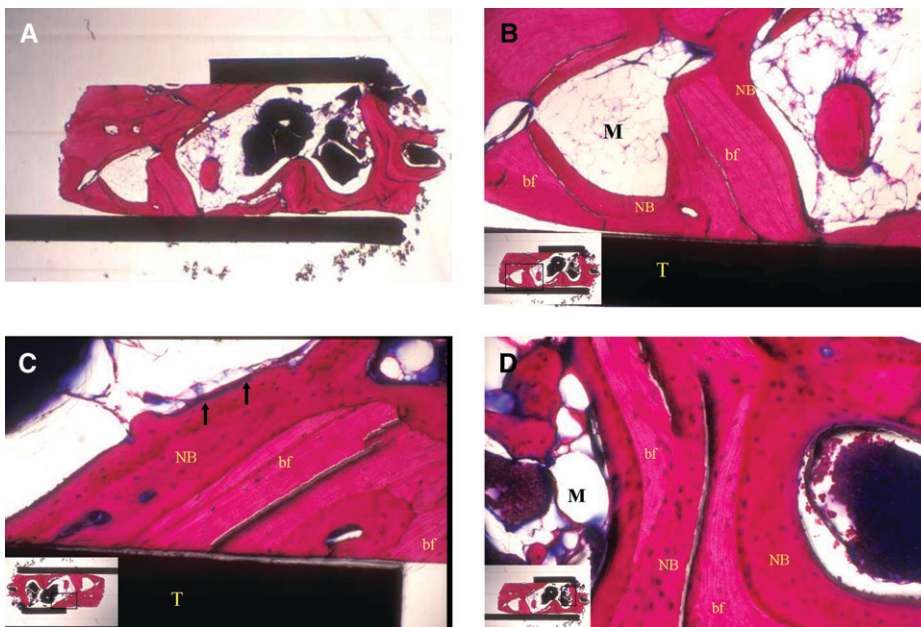


Figure 4.

A) Histologic sections. Low-power view of a trephine and bone core taken from an augmented ridge after 6 months of healing. The trephine is filled with bone fragments and newly remodeled bone (red). **B)** A higher-power view of section A showing bone fragments (bf) in the trephine (T) that have evidence of remodeling, new bone (NB) surrounding the demineralized freeze-dried bone allograft, and marrow tissue (M). **C)** Histologic section study showing an osteoid seam (arrows) lining newly remodeled bone (NB) around the bone fragments (bf). The new bone appears woven and has viable osteocytes. T = trephine. **D)** Histologic section showing almost complete remodeling of bone fragments (bf) and replacement with new bone (NB). Viable osteocytes are visible in the bony matrix, and adipocytes are present in the marrow-like tissue (M). (Paragon stain; original magnification: A, $\times 2.5$; B, $\times 10$; C and D, $\times 25$.)

Collagen was the first bioabsorbable membrane material to be widely used in GBR. Collagen membranes have been used in combination with autogenous bone,²³ xenografts,¹⁷ hydroxyapatite,¹⁵ and other bone substitutes²² and have been associated with success rates comparable to those achieved with non-resorbable ePTFE membranes.^{13,18,19} Such findings support the use of a bioabsorbable barrier membrane for the regeneration of bone. Moreover, the use of a bioabsorbable membrane may decrease

the risk for a membrane infection if a soft tissue dehiscence occurs postoperatively.^{3,7} However, there are drawbacks to collagen membranes. Because of its relatively short absorption time, collagen loses its barrier function within 2 or 3 months;⁷ therefore, it may not provide sufficient time for completion of the bone-regeneration process. There is also some evidence that collagen does not adequately exclude soft tissue.²⁴ Finally, some subjects refuse treatment involving products derived from animals on the basis of religious and/or ethical beliefs.

The limitations of collagen membranes provoked the search for a bioabsorbable polymer substitute for collagen in GBR that began in the late 1990s. Lekovic et al.³ evaluated the efficacy of a membrane composed of glycolide and lactic acid polymers for alveolar ridge augmentation after tooth extraction in 16 subjects. Bone grafts were not used in that study. Compared to controls, sites in which the membranes were placed exhibited significantly less horizontal ridge resorption. In a case report, Miller et al.²¹ used bioabsorbable polymer membranes from two manufacturers in conjunction with autogenous bone to augment the alveoli of a patient who lost two teeth after being kicked in the mouth during a soccer game. Six months later, both sites were completely regenerated with hard tissue that

had the histologic appearance of normal bone. Mellonig et al.^{14,25} conducted a two-part histomorphometric assessment of a prototype bioabsorbable PGA/TMC membrane used for GBR in large, dehiscence-type defects in dogs. When the membrane was used without a graft material, the investigators failed to observe an increase in ridge width relative to untreated sites.²⁵ In contrast, when the membrane was used in combination with an allograft, it resulted in a mean alveolar ridge width that was more than twice that detected at control

Table 2.
Ridge Width Changes for Membrane Exposure Status

	n	At the Crest (mm)		4 mm Apical to the Crest (mm)	
		Mean (SD)	Range	Mean (SD)	Range
Exposed and removed	8	1.75 (1.4)	0.5 to 4.0	2.0 (1.5)	0 to 5.0
Exposed, not removed	22	3.1 (1.8)	0 to 7.0	3.3 (1.8)	0 to 7.0
Covered	42	2.9 (1.7)	0 to 6.5	3.3 (1.9)	-0.5 to 7.0

sites (4.6 versus 2.0 mm).¹⁴ Values for bone contact, bone height, and area of newly formed bone were also markedly higher than those from controls (70% versus 6%, 6 mm versus 2 mm, and 12 mm² versus 6 mm², respectively). The authors considered these results comparable to those provided by the combination of a non-resorbable ePTFE membrane and an allograft, although they also noted that the prototype PGA/TMC membrane they studied may have absorbed too quickly.¹⁴ The LT PGA/TMC membrane used in the current study has a substantially longer retention time.

Our investigation was not a comparative trial, but our results may be examined in relation to the findings of two clinical studies^{6,23} that also evaluated changes in ridge width after GBR. In a series of 40 subjects, Buser et al.⁶ used corticocancellous autografts, bone chips, and non-resorbable ePTFE membranes to augment the ridge in 66 potential implantation sites narrower than 5 mm. Before the augmentation procedure, the mean ridge width, measured 2 mm apical to the alveolar crest, was 3.5 mm (range, 2 to 4.5 mm). When the ePTFE membranes were removed 7 to 13 months later, the mean width was 7 mm (range, 5 to 10 mm). Subsequent placement of titanium implants was successful in all 40 subjects. The mean increases in ridge width achieved by Buser's group were very similar to those of our study. However, they used the standard GBR method, which, unlike the technique we used, required a bone-harvesting procedure and frequently a second operation to remove the membrane. In the study conducted by von Arx and Buser,²³ autogenous block grafts, anorganic bovine bone mineral, and collagen membranes were used for horizontal ridge augmentation of 58 sites in 42 subjects. The mean ridge width at the crest was 3 mm (range, 0.5 to 5 mm) before the GBR procedure and 8 mm (range, 6 to 10 mm) after an average of 5.8 months (range, 4.5 to 13.5 months). Although the mean gain in ridge width (4.6 mm) was greater than that attained in our study, the augmentation tech-

nique used by von Arx and Buser was much more complex than our method and required harvesting of block grafts from the symphysis or the retromolar area. Moreover, we regard the ridge widths obtained in our series (5.2 mm at the crest and 7.5 mm apical to the crest) as adequate for the subsequent placement of endosseous implants.

On average, our histomorphometric analysis showed that the 48 biopsy specimens consisted of 57% bone (allograft material plus new bone), 20% new bone, and 43% soft tissue and space. A histomorphometric study by Brunel et al.¹⁵ of specimens obtained 8 months after a GBR procedure using a collagen membrane and a synthetic hydroxyapatite graft material yielded similar results: 49% for mean bone surface area and 39% for medullary space surface area. They reported that this defect fill made placement of implants possible in all 14 sites studied, and only one of the implants failed during a 7-year follow-up period.

Membrane exposure has been associated with diminished results.²⁶ In this study, 42% of the sites were exposed. When an exposure did not lead to the removal of the membrane, the mean gain in ridge width was similar to the sites where the membrane remained covered. The premature exposure of these membranes, when managed with the protocol for prevention of infection by using local application of 0.12% chlorhexidine, did not lead to diminished results. During the healing of these sites, the integrity of the membrane remained intact for an extended period of time postexposure. The maintenance of the integrity of the barrier function may be beneficial. However, this does add a management concern for these sites and should be avoided. Premature removal of the membranes because of infection negatively impacted the gain in width.

CONCLUSIONS

Definitive evidence that the extent of bone regeneration achieved with the LT PGA/TMC membrane is comparable or superior to that associated with other materials can come only from randomized controlled studies. We recognize this as a limitation of the current study. However, our results indicated that GBR procedures involving this membrane in conjunction with a bone allograft produce lateral ridge augmentation sufficient for placement of endosseous implants in healed bony sites. Additionally, such an approach provides several benefits for patients relative to the use of non-resorbable membranes in combination with autogenous bone. It is less invasive, less painful, less expensive, and facilitates the completion of treatment in a shorter period of time. Collectively, these properties suggest that the use of the LT PGA/TMC membrane along with a bone allograft represents a reasonable alternative to previously described lateral ridge-augmentation procedures.

ACKNOWLEDGMENTS

The authors thank W.L. Gore & Associates, Inc., for financial support for this study and the preparation of the manuscript. The authors also thank Renée J. Robillard, scientific writer, W.L. Gore & Associates, Inc., and Elizabeth Bolton, editorial support, University of Alabama at Birmingham, for writing and editorial assistance. Dr. Geurs has received lecture fees from Exactech Dental Biologics, the company that provided the biologic carrier used in this study. At the time this study was conducted, Dr. Kellar was Product Specialist at W.L. Gore & Associates, Inc., and held vested stock in the company. Drs. Korostoff, Vassilopoulos, Kang, Jeffcoat, and Reddy report no conflicts of interest related to this study.

REFERENCES

- Levin L, Nitzan D, Schwartz-Arad D. Success of dental implants placed in intraoral block bone grafts. *J Periodontol* 2007;78:18-21.
- Bartee BK. Extraction site reconstruction for alveolar ridge preservation. Part 1: Rationale and materials selection. *J Oral Implantol* 2001;27:187-193.
- Lekovic V, Camargo PM, Klokkevold PR, et al. Preservation of alveolar bone in extraction sockets using bioabsorbable membranes. *J Periodontol* 1998;69:1044-1049.
- Hämmerle CH, Karring T. Guided bone regeneration at oral implant sites. *Periodontol 2000* 1998;17:151-175.
- Fiorellini JP, Nevins ML. Localized ridge augmentation/preservation. A systematic review. *Ann Periodontol* 2003;8:321-327.
- Buser D, Dula K, Hirt HP, Schenk RK. Lateral ridge augmentation using autografts and barrier membranes: A clinical study with 40 partially edentulous patients. *J Oral Maxillofac Surg* 1996;54:420-432.
- Buser D, Dula K, Hess D, Hirt HP, Belser UC. Localized ridge augmentation with autografts and barrier membranes. *Periodontol 2000* 1999;19:151-163.
- King GN. New regenerative technologies: Rationale and potential for periodontal regeneration: 1. New advances in established regenerative strategies. *Dent Update* 2001;28:7-12.
- Fugazzotto PA. Report of 302 consecutive ridge augmentation procedures: Technical considerations and clinical results. *Int J Oral Maxillofac Implants* 1998;13:358-368.
- Buser D, Dula K, Lang NP, Nyman S. Long-term stability of osseointegrated implants in bone regenerated with the membrane technique. 5-year results of a prospective study with 12 implants. *Clin Oral Implants Res* 1996;7:175-183.
- Buser D, Ingimarsson S, Dula K, Lussi A, Hirt HP, Belser UC. Long-term stability of osseointegrated implants in augmented bone: A 5-year prospective study in partially edentulous patients. *Int J Periodontics Restorative Dent* 2002;22:109-117.
- Nevins M, Mellonig JT, Clem DS 3rd, Reiser GM, Buser DA. Implants in regenerated bone: Long-term survival. *Int J Periodontics Restorative Dent* 1998;18:34-45.
- Hurzeler MB, Kohal RJ, Naghshbandi J, et al. Evaluation of a new bioresorbable barrier to facilitate guided bone regeneration around exposed implant threads. An experimental study in the monkey. *Int J Oral Maxillofac Surg* 1998;27:315-320.
- Mellonig JT, Nevins M, Sanchez R. Evaluation of a bioabsorbable physical barrier for guided bone regeneration. Part II. Material and a bone replacement graft. *Int J Periodontics Restorative Dent* 1998;18:139-149.
- Brunel G, Brocard D, Duffort JF, et al. Bioabsorbable materials for guided bone regeneration prior to implant placement and 7-year follow-up: Report of 14 cases. *J Periodontol* 2001;72:257-264.
- Cosci F, Cosci R. Guided bone regeneration for implant placement using absorbable collagen membranes: Case presentations. *Pract Periodontics Aesthet Dent* 1994;6:35-41.
- Zitzmann NU, Schärer P, Marinello CP, Schüpbach P, Berglundh T. Alveolar ridge augmentation with Bio-Oss: A histologic study in humans. *Int J Periodontics Restorative Dent* 2001;21:288-295.
- Bunyaratavej P, Wang HL. Collagen membranes: A review. *J Periodontol* 2001;72:215-229.
- Schwartzmann M. Use of collagen membranes for guided bone regeneration: A review. *Implant Dent* 2000;9:63-66.
- Simon BI, Von Hagen S, Deasy MJ, Faldu M, Resnansky D. Changes in alveolar height and width following ridge augmentation using bone graft and membranes. *J Periodontol* 2000;71:1774-1791.
- Miller NA, Penaud J, Kohler C, Ambrosini P. Regeneration of bone graft donor sites. *Clin Oral Implants Res* 1999;10:326-330.
- Wang HL, Boyapati L. "PASS" principles for predictable bone regeneration. *Implant Dent* 2006;15:8-17.
- von Arx T, Buser D. Horizontal ridge augmentation using autogenous block grafts and the guided bone regeneration technique with collagen membranes: A clinical study with 42 patients. *Clin Oral Implants Res* 2006;17:359-366.
- Stavropoulos F, Dahlin C, Ruskin JD, Johansson C. A comparative study of barrier membranes as graft protectors in the treatment of localized bone defects. An experimental study in a canine model. *Clin Oral Implants Res* 2004;15:435-442.
- Mellonig JT, Nevins M, Sanchez R. Evaluation of a bioabsorbable physical barrier for guided bone regeneration. Part I. Material alone. *Int J Periodontics Restorative Dent* 1998;18:129-137.
- Machtei EE. The effect of membrane exposure on the outcome of regenerative procedures in humans: A meta-analysis. *J Periodontol* 2001;72:512-516.

Correspondence: Dr. Nicolaas Geurs, Department of Periodontology, University of Alabama at Birmingham School of Dentistry, SDB 412, 1530 3rd Ave. S., Birmingham, AL 35294-0007. Fax: 205/934-7901; e-mail: ngeurs@uab.edu.

Submitted November 19, 2007; accepted for publication January 2, 2008.