

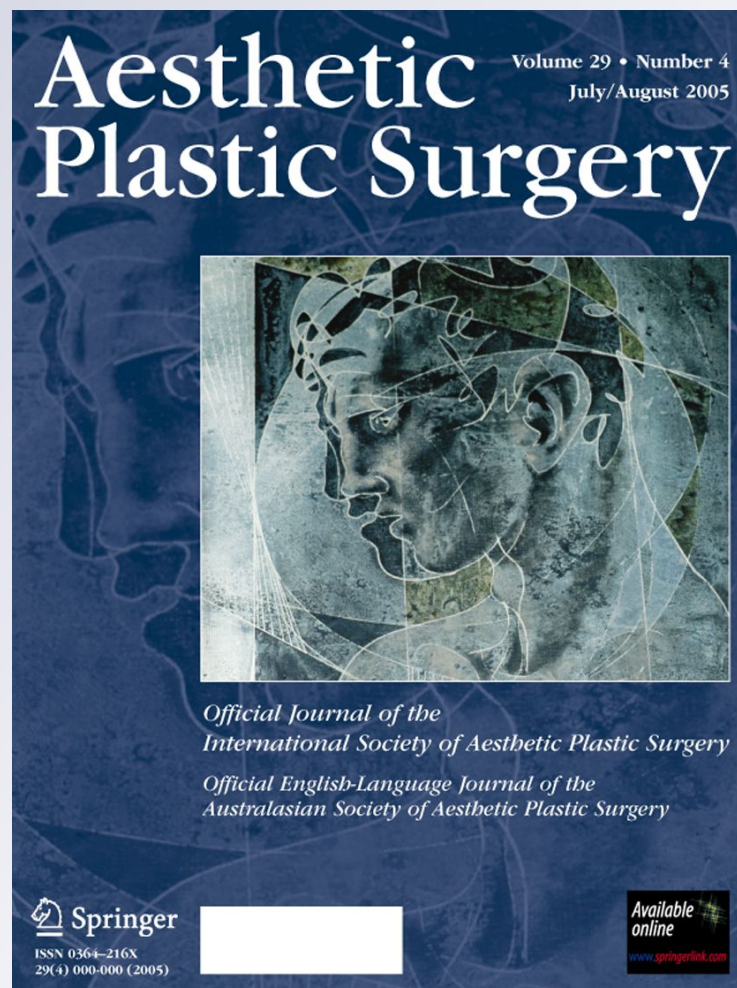Human Cell-Conditioned Media Produced Under Embryonic-Like Conditions Result in Improved Healing Time After Laser Resurfacing

*M. P. Zimmer, J. N. Mansbridge,
M. Taylor, T. Stockton, M. Hubka,
M. Baumgartner, L. Rheins, K. Hubka,
E. N. Brandt, R. Kellar & G. K. Naughton*

Aesthetic Plastic Surgery

ISSN 0364-216X

Aesth Plast Surg
DOI 10.1007/
s00266-011-9787-8



Your article is protected by copyright and all rights are held exclusively by Springer Science +Business Media, LLC and International Society of Aesthetic Plastic Surgery. This e-offprint is for personal use only and shall not be self-archived in electronic repositories. If you wish to self-archive your work, please use the accepted author's version for posting to your own website or your institution's repository. You may further deposit the accepted author's version on a funder's repository at a funder's request, provided it is not made publicly available until 12 months after publication.

Human Cell-Conditioned Media Produced Under Embryonic-Like Conditions Result in Improved Healing Time After Laser Resurfacing

M. P. Zimmer · J. N. Mansbridge · M. Taylor · T. Stockton ·
M. Hubka · M. Baumgartner · L. Rheins · K. Hubka ·
E. N. Brandt · R. Kellar · G. K. Naughton

Received: 8 January 2011 / Accepted: 18 June 2011
© Springer Science+Business Media, LLC and International Society of Aesthetic Plastic Surgery 2011

Abstract

Background Laser resurfacing procedures are continuing to grow in popularity as patients select less invasive procedures for rejuvenation of photo-damaged and aging skin. However, although physicians have begun exploring options to aid in postlaser healing, currently available treatments have little clinical evidence to support their use for wounded skin.

Methods When grown under conditions of very low oxygen and suspension, a simulation of the embryonic environment, neonatal cells have been found to produce proteins and growth factors in types and quantities similar to those of fetal cells. The human cell-conditioned media (hCCM) produced by the cells was extracted and formulated into a gel to evaluate its efficacy in the healing of postlaser wounds.

Results A split-face clinical evaluation of the material was performed, with 42 subjects undergoing combination ablative and nonablative laser procedures. Three concentrations of the hCCM were tested ($\times 0.1$, $\times 1.0$, $\times 10.0$),

and a dose–response trend was seen in the blinded physician evaluation, particularly in the assessment of crusting. In addition, transepidermal water loss readings showed a significant difference ($p \leq 0.05$), indicating a more rapid return to normal skin barrier function with the active treatment. Histopathologic evaluation of subject biopsies showed reduced inflammation and a more normal epidermal appearance in the active treatment sites.

Conclusions The results of this clinical evaluation support the use of the soluble hCCM produced under embryonic-like conditions to accelerate wound healing after laser resurfacing procedures. The utility of the $\times 10$ concentration appears to promote more rapid, scarless wound healing after resurfacing procedures and more normal skin recovery.

Keywords Human cell conditioned media · Laser resurfacing · Wound healing · Aging · Rejuvenation · Regenerative medicine

M. P. Zimmer · J. N. Mansbridge · M. Hubka (✉) ·
M. Baumgartner · L. Rheins · K. Hubka ·
E. N. Brandt · R. Kellar · G. K. Naughton
Histogen Inc, 10655 Sorrento Valley Road, San Diego,
CA 92121, USA
e-mail: mhubka@histogeninc.com

E. N. Brandt
e-mail: ebrandt@histogeninc.com

M. Taylor
Gateway Aesthetic Institute and Laser Center, 440 West 200
South, Suite 250, Salt Lake City, UT 84101, USA

T. Stockton
Stockton Dermatology, 16611 S. 40th Street, Phoenix, AZ
85048, USA

Laser procedures for resurfacing of facial skin have continued to grow in popularity in the United States and throughout the world. In 2008, the total number of cosmetic laser procedures performed in the United States rose to 570,880, a 12% increase from the previous year. Over the past few years, a trend has been seen in the cosmetic surgery industry, with patients increasingly opting for less invasive procedures to rejuvenate photo-damaged skin and to achieve anti-aging effects. According to the American Academy of Cosmetic Surgery Census, laser resurfacing has seen the largest increase among less invasive procedures—370% since 2005 [1].

Since the introduction of laser resurfacing for the treatment of photo-damaged skin in the 1980 s, new

techniques have been developed both to improve cosmesis and to minimize side effects such as patient discomfort and long recovery times. However, patients still can expect the uncomfortable healing process after laser resurfacing to last from 10 days to 4 weeks, with patients reluctant to appear in public during that time.

Although physicians have begun exploring options to aid in the treatment of postlaser wounding, currently available products have little clinical evidence to support their use on wounded skin, and petrolatum continues to be the standard of care.

It is well established that surgeries performed in the womb do not produce scarring during the earlier stages of fetal development. The unique healing characteristics of fetal tissue produce a regenerative effect [2]. A proprietary tissue-engineering technology has been developed to mimic the conditions of the embryonic environment, triggering neonatal cells to produce a soluble human extracellular matrix material, which is embryonic-like in nature.

Neonatal cells grown under conditions of low oxygen and bead suspension, a simulation of the embryonic environment, have been found to produce proteins and growth factors in types and quantities similar to those of fetal cells. The human cell-conditioned media (hCCM) contains a variety of growth factors and cytokines such as vascular endothelial growth factor (VEGF), keratinocyte growth factor (KGF), and interleukin-8 (IL-8) that have been previously reported to play key roles in the wound-healing process [3–6].

A pilot “proof-of-concept” clinical evaluation was performed to determine whether a topical gel containing this embryonic-like hCCM material can support facial wound healing after laser resurfacing procedures. In this randomized, double-blind, placebo-controlled study, 49 subjects received either the hCCM-containing gel (ReGenica Facial Rejuvenation Complex, Histogen Aesthetics, San Diego, CA) or a placebo control for use after combination ablative and nonablative laser procedures.

The results of this pilot clinical evaluation showed accelerated wound healing in subjects using the active gel. On day 7, the subjects who used the active gel showed greater improvement in erythema and reepithelization of the perioral and periocular regions than those who used the placebo control, as determined by blinded, clinical evaluation of photographs and bioinstrumental mexameter measurements. A statistically significant reduction in rescue petrolatum use was reported in the active lotion-treated subjects compared with the placebo subjects. No safety concerns were reported with either the active or the placebo treatment [7].

With proof-of-concept results supporting the use of the hCCM-containing gel for wound-healing applications, the reported study was undertaken to begin evaluating the

hypothesis that similar results of accelerated wound healing would be seen in a split-face model. This experimental design was implemented to reduce the variables of healing and age differences between subjects. It also was hypothesized that the postlaser healing factors would follow a dose–response effect based on the concentration of hCCM in the gel to improve cutaneous healing in the critical 14 days after laser resurfacing procedures.

Materials and Methods

Active Material Production and Characterization

Scalable 1-l bioreactors were used to grow neonatal cells on dextran microcarrier beads in suspension under hypoxic conditions using standard tissue culture procedures and media. Through this proprietary technology process, two unique embryonic-like products were produced: a soluble hCCM and an insoluble human extracellular matrix that contains various growth factors known to be critical in wound healing. These culture conditions were optimized without the need for fetal bovine serum in the final product, and the oxygen concentration (1–5%) of the cultures was monitored and controlled during the entire period. The cultures were harvested after 8 weeks, and the soluble hCCM was concentrated using a 10-kDa molecular weight cutoff filter and tested for endotoxin, sterility, VEGF, and KGF concentration levels.

Clinical Evaluation

After obtaining human subject approval and informed consent from the volunteers, 42 subjects were enrolled in the study at two separate sites. For the clinical evaluation of the hCCM-containing gel, male and female subjects ages 40 to 70 years were enrolled. The subjects included in the study had Fitzpatrick scores of 2 to 4 and at least moderate scores on the Manifestation of Photodamage Scale [8].

The study subjects were treated with an ablative 2,940-nm laser (Palomar Medical Technologies, Burlington, MA, USA) in periocular and perioral areas and with a nonablative 1,540-nm laser (Palomar Medical Technologies) on the remainder of the face. The number of pulses with each of the lasers was identical across the subjects to ensure equal energy exposure. Photographs were taken at baseline and on days 3, 5, 7, and 14 after treatment using a Canfield system and a Nikon d80 camera (Canfield, Fairfield, NJ, USA).

The subjects were divided into three subgroups, each of which was treated on the randomly selected half of the face with a $\times 0.1$, $\times 1.0$, or $\times 10.0$ concentration of hCCM in a gel formulation applied directly to the skin immediately

after the laser procedure without any additional cleaning of the skin. The control treatment, consisting of the gel formulation not containing soluble hCCM, was applied to the opposite side of each subject's face in a similar fashion. The subjects returned each day for controlled application of the test articles, with at least three additional applications performed by the subject each day for the 14-day length of the study.

Clinical Grading

The clinician used a 4-point scale of 0 (none) to 4 (severe) to grade the amount of erythema, edema, dryness, and peeling at baseline and on days 3, 7, and 14. Two dermatologists were provided with blind-coded photographs and asked independently to score erythema, edema, and crusting on the same 4-point scale for the same time points.

Vapometer

In addition to clinical and independent dermatologist grading, transepidermal water loss, another indication of the healing process, was measured using a Vapometer device (Delphin Technology, Ltd, Hyvinkaa, Finland). This water loss measurement was used as an indicator of reepithelialization based on the principle that evaporation decreases with healing of the natural skin barrier.

Results

The hypoxia culture condition promotes expression of genes and proteins associated with increased wound healing.

The soluble hCCM produced by culturing primary neonatal dermal cells under proprietary conditions of low oxygen and bead suspension was compared with the products of these cells cultured in a monolayer under normoxic conditions of atmospheric oxygen (approximately 21%). The cell cultures grown in suspension under hypoxic conditions demonstrated increased secreted VEGF protein levels and undetectable protein levels of transforming growth factor β (TGF β) as measured by enzyme-linked immunoassay (ELISA). Produced by the normoxic cell cultures, TGF β has been implicated as a factor contributing to fibrosis and skin scarring after wounding.

In addition, the gene expression levels of the hypoxic cells producing the hCCM were compared with the normoxic cell cultures using DNA microarray technology. Samples of total RNA from both cell lines were compared using Agilent (Agilent Technologies, Santa Clara, CA, USA) whole human genome microarrays for global gene expression.

The results indicate that the hypoxic culture conditions result in a 15-fold increase in mRNA expression for hypoxia-inducible factor (HIF1A) and a 5-fold decrease in its respective inhibitor. This suggests that this hCCM material experiences a low-oxygen-tension environment (hypoxia) because the HIF1A messenger RNA is upregulated and its inhibitor is downregulated. Furthermore, the VEGF (4.33-fold increase), KGF (11.51-fold increase), and IL-8 (5.81-fold increase) levels also were upregulated under these culture conditions. Both VEGF and KGF are reported to be upregulated in hypoxic environments and to facilitate events in the wound-healing process [3–6].

Rate of Wound Healing

In the second clinical evaluation of the hCCM-containing gel as a postlaser treatment, the 42 subjects were divided into groups of 14 to evaluate three different concentrations ($\times 0.1$, $\times 1.0$, and $\times 10.0$) of the active product. The subjects received the active product for use on half of the face and the vehicle control for use on the remaining half, with each half allocated blindly and randomly. The patients returned daily for controlled use application by the clinical staff. (Fig. 1).

Clinical evaluation of the blinded subject photos by independent dermatologists showed a dose–response trend, with the $\times 10$ concentration of the hCCM-containing gel having the most apparent effect on subject healing. Differences between the concentrations can be seen in the physician assessment of crusting (Fig. 2), with the most incremental difference on day 7.

Transepidermal Water Loss

Overall, the hCCM-containing gel in varying concentrations outperformed the control gel. The transepidermal water loss readings using the Vapometer unit, which measures the evaporation rate, ambient relative humidity, and temperature, showed a statistically significant difference ($p \leq 0.05$) between the control and active gels on days 3 and 7. This indicates a more rapid reepithelialization and return to the normal skin barrier function with the active treatment than with the control treatment.

As can be seen in Fig. 3, treatment sites receiving the hCCM-containing gel returned to baseline levels (prelaser treatment) on day 7, with the control-site measurements remaining substantially higher. This indicates that healing of the active treatment side was nearly complete, whereas the control site skin barrier remained disrupted.

Photographic Documentation of Wound Healing

Clinical grading of the subject photographs by the blinded independent dermatologists for edema and erythema

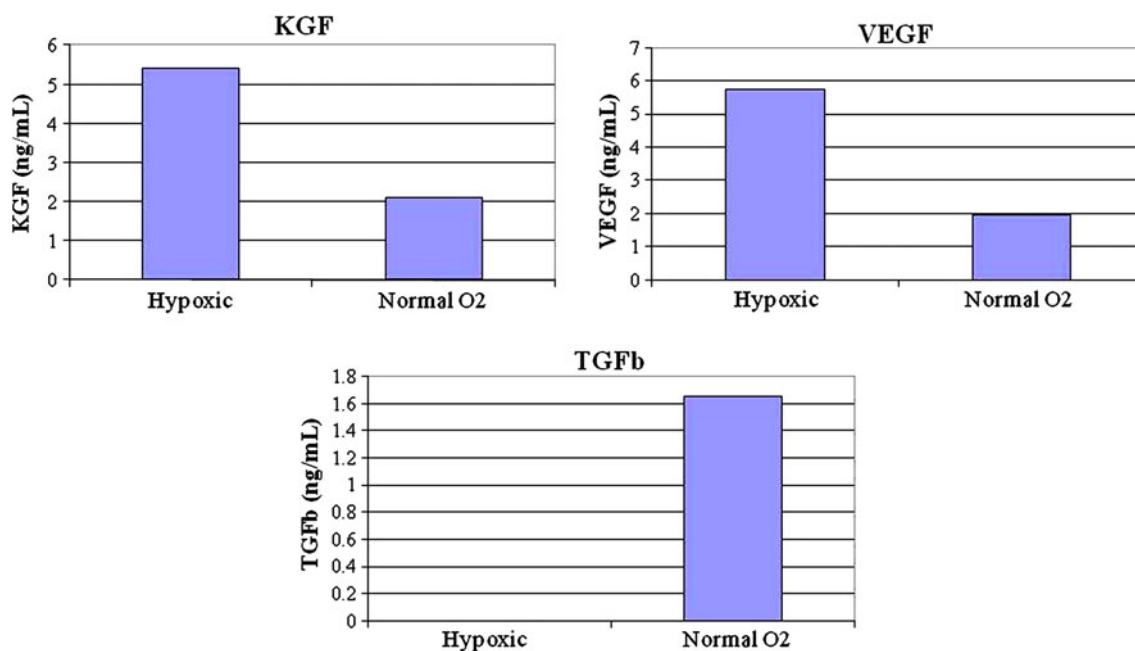


Fig. 1 Effects of hypoxia on protein secretion

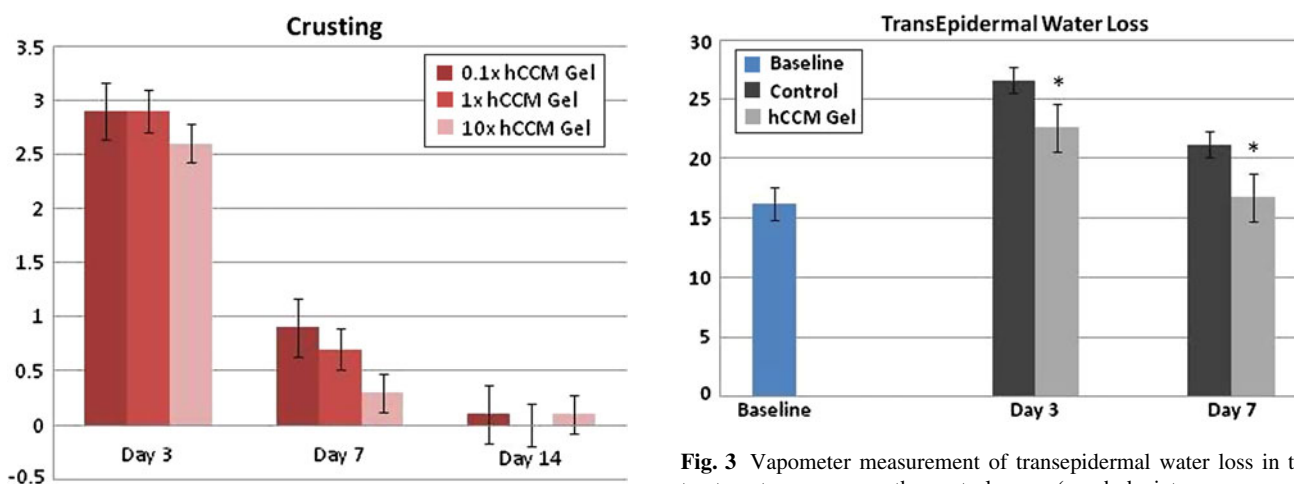


Fig. 2 Blinded physician evaluation of crusting using a 4-point scale (graph depicts mean scores in each treatment group) ($n = 41$)

Fig. 3 Vapometer measurement of transepidermal water loss in the treatment group versus the control group (graph depicts mean scores). The treatment group shows a return to baseline levels, with a mean of 16.75 on day 7 compared with the mean of 16.2 at baseline ($n = 41$)

showed less redness and swelling on the active gel side of the face. A visible difference could be seen in edema and erythema across the subjects, with those receiving the highest concentration of active gel ($\times 10.0$) showing the most apparent visible difference (Fig. 4).

Biopsies

Three subjects, one from each treatment group, were identified in a randomized fashion to receive two 3-mm punch biopsies, one each from the left and right peri-auricular regions at baseline and 14 days after the

procedure. Histopathologic evaluation was performed on paraffin-embedded, hematoxylin and eosin-stained biopsy sections to identify indicators associated with the healing process, particularly those associated with inflammation. Sites treated with the hCCM-containing gel (Fig. 5) displayed a reduced level of leukocyte infiltration, indicating less inflammation than at the control-treated sites. The sites treated with the hCCM-containing gel also showed a cell density and extracellular matrix consistency and exhibited a defined stratum germinativum layer and organized upper layers of the epidermis that were more normal in appearance than the control-treated sites.

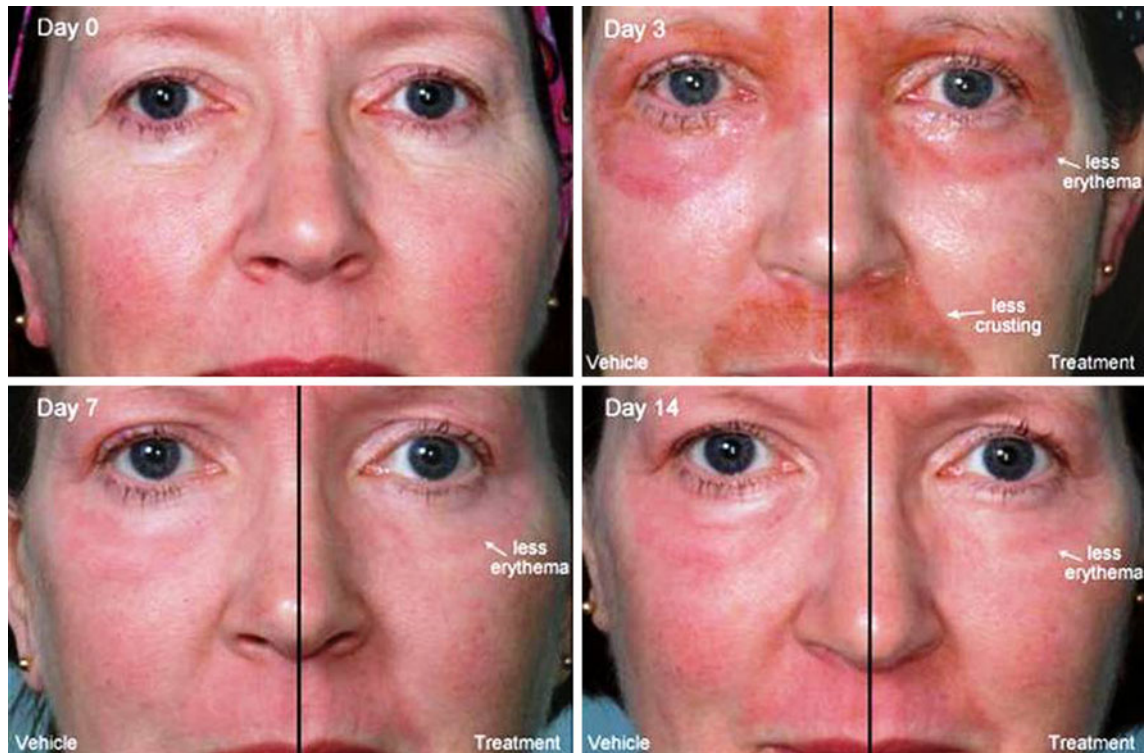


Fig. 4 Observable reduction in erythema on days 3, 7, and 14 on left side of face treated with the $\times 10.0$ concentration of active gel compared with the vehicle control

Discussion

An initial whole-face postlaser study was performed using the hypoxic human cell-conditioned medium in a gel suspension and showed more rapid healing times than shown by age-matched patients, with active subjects experiencing reduced erythema and reepithelialization in half the time required by the control subjects. This was followed by a split-face design (inpatient control) study performed at two centers with a total of 42 subjects. It was a controlled-use study in which all the subjects returned to the clinic sites daily for reapplication of the test article and vehicle control.

Furthermore, three different concentrations ($\times 10.0$, $\times 1.0$, and $\times 0.1$) of the hCCM gel were tested. Analysis of the data showed a dose response, with the $\times 1.0$ concentration showing better overall improvement than the $\times 0.1$ concentration, and with the $\times 10.0$ concentration exhibiting the best efficacy. This mirrored the results of the initial full-face clinical study, as previously reported [7]. Reduced erythema, more rapid recovery of the skin barrier, and overall results were improved. The subjects experienced no adverse events.

A review of the gene expression array data and the secreted factors present within the hypoxic cultures showed that they are consistent with the scarless wound-healing

factors found in the embryonic environment. Upregulation of factors associated with healing, such as VEGF, and concurrent downregulation of factors associated with scarring, specifically TGF β , lend to the improved healing effect [2, 9]. Whereas no scars were reported in the control-treated sites, blinded independent physician analysis of the photographs graded the pictures of the hCCM-treated side consistently better on day 14, with localized areas of erythema noted on the control-treated side.

Embryonic-like extracellular matrix proteins augment normal adult wound healing and appear to be more representative of wound healing as it first occurs in utero, particularly more rapid scarless wound healing. This could have immense clinical utility. The physician grading, photographic assessment, and biopsy findings are consistent with a cosmetic outcome associated with an improved healing response. Histopathologic evaluation indicated that sites treated with the hCCM test article display a reduced level of leukocyte infiltration indicative of less inflammation than the control-treated sites. These sites also show a more normal cell density and extracellular matrix consistency. In addition, they exhibit a defined stratum germinativum layer and organized upper layers of the epidermis that are more normal in appearance than the control-treated sites.

Further studies to evaluate the hCCM formulation, including higher hCCM concentrations, for postlaser

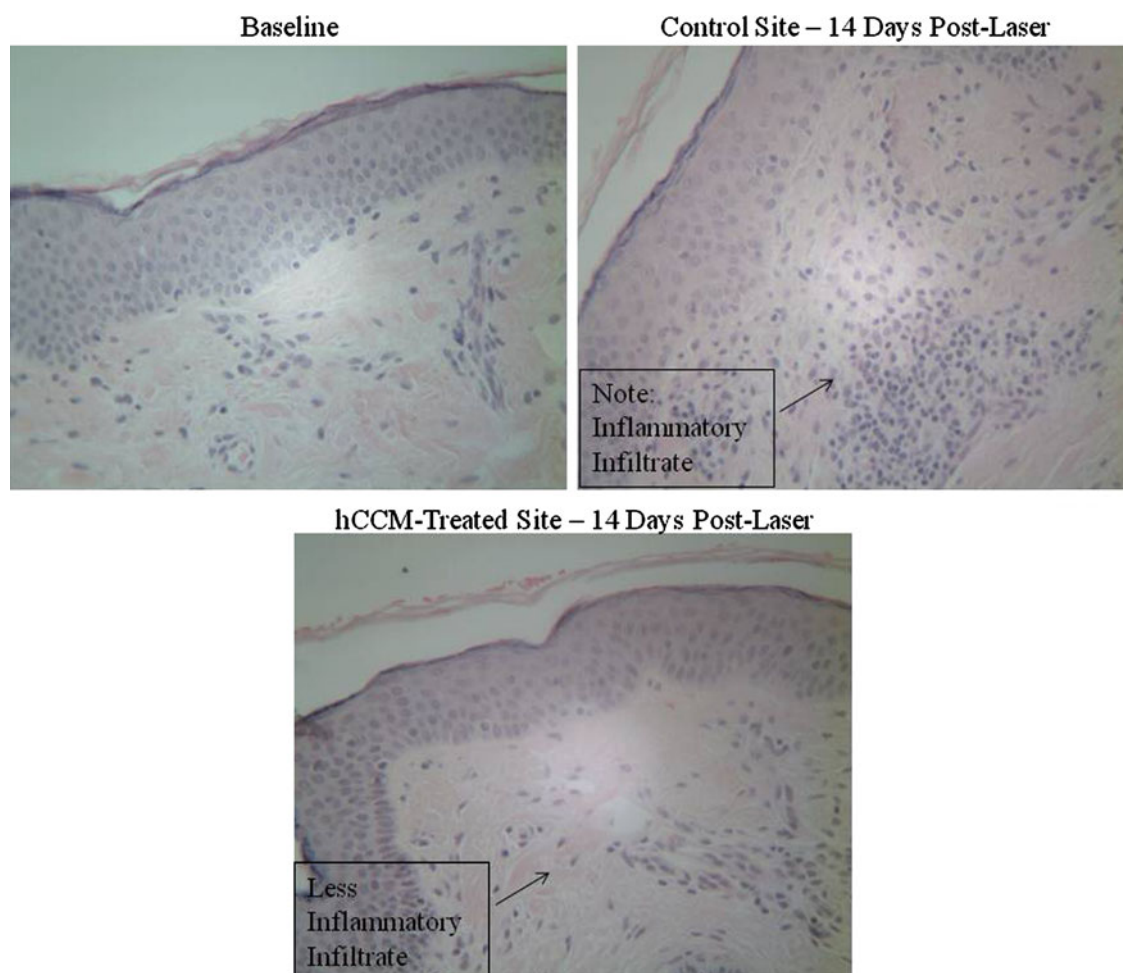


Fig. 5 Less inflammatory response seen in sites treated with human cell-conditioned media (hCCM) at the 14-day time point

healing would be beneficial to support the findings described in this report. In addition, evaluation of the hCCM and its hypoxic secreted factors are underway to examine its effectiveness in improving the texture, coloration, and wrinkling of normal skin. Due to its composition of growth factors important for promoting wound healing and growth, we believe that the hCCM also may have benefits for treating other types of wounds and dermatologic conditions. Work currently is underway to examine the utility of the conditioned medium in these applications.

Conclusions

In the preliminary clinical trial described in this report, 42 healthy volunteers were enrolled in a clinical evaluation to test the efficacy of a formulation containing a human cell-conditioned medium in accelerated wound healing after laser resurfacing of the face. The results of this randomized, double-blind, placebo-controlled, split-face study

support the use of this formulation to accelerate wound healing after facial laser resurfacing. In addition, there was an apparent dose response, with the highest concentration ($\times 10.0$) having the most efficacy.

Use of a controlled-production hCCM that contains products produced under simulated embryonic conditions appears to accelerate wound healing, as seen by the transepidermal water loss data. In addition, the conditioned media appears to promote healing with less inflammation and more normal skin recovery, as noted in the biopsy evaluation. The secreted cytokines, including factors such as KGF and VEGF, aid healing of the skin after the procedure where the outer layer has been compromised by the procedure.

Disclosure M. Hubka serves as Director of Clinical Affairs, M. P. Zimmer as Director of Applied Research, J. N. Mansbridge as Chief Scientific Officer, M. Baumgartner as Director of Engineering, and K. Hubka as Biomedical Tissue Engineer of Histogen, Inc. E. N. Brandt serves as an employee of Histogen, Inc. All receive a salary and stock options. G. K. Naughton serves as Chairman and CEO for Histogen,

Inc and receives stock and other interests. The authors declare that they have no other potential conflicts of interest to disclose.

References

1. American Academy of Cosmetic Surgery (2009) Procedural census, February 2010. Prepared by RH Research, Chicago, IL
2. Adzick NS, Lorenz HP (1994) Cells, matrix, growth factors, and the surgeon: the biology of scarless fetal wound repair. *Ann Surg* 220:10–18
3. Henemyre-Harris CL, Adkins AL et al (2008) Addition of epidermal growth factor improves the rate of sulfur mustard wound healing in an in vitro model. *Eplasty* 8:e16
4. Marti GP, Mohebi P et al (2008) KGF-1 for wound healing in animal models. *Methods Mol Biol* 423:383–391
5. Galiano RD, Tepper OM et al (2004) Topical vascular endothelial growth factor accelerates diabetic wound healing through increased angiogenesis and by mobilizing and recruiting bone marrow-derived cells. *Am J Pathol* 164:1935–1947
6. Saaristo A, Tammela T et al (2006) Vascular endothelial growth factor C accelerates diabetic wound healing. *Am J Pathol* 169:1080–1087
7. Kellar RS, Hubka M et al (2009) Hypoxic conditioned culture medium from fibroblasts grown under embryonic-like conditions supports healing following postlaser resurfacing. *J Cosmetic Dermatol* 8:190–196
8. Griffiths CE, Wang TS, Hamilton TA et al (1992) A photometric scale for the assessment of cutaneous photo damage. *Arch Dermatol* 128:347–351
9. Eslami A, Gallant-Behm CL et al (2009) Expression of Integrin $\alpha v \beta 6$ and TGF- β in scarless vs scar-forming wound healing. *J Histochem Cytochem* 57:543–557